PITUITARY ADENOMA
Dr.M. YASSER METWALLY

- INTRODUCTION & PATHOLOGY
- NORMAL ANATOMY
- PITUITARY MICROADENOMA
- PITUITARY MACROADENOMA
- CONTRAST ISSUES IN PITUITARY ADENOMAS
- PITUITARY APOPLEXY
- EMPTY SELLA SYNDROME

INTRODUCTION & PATHOLOGY

Originally termed chromophobe adenomas, endocrine-inactive pituitary tumors were once considered the largest group of pituitary tumors. With advances in endocrinologic testing and modern immunohistochemical and immunoelectron microscope techniques, the incidence of adenomas with no evidence of hypersecretion or endocrine activity has decreased to about 25 per cent of pituitary adenomas. Histologically, these adenomas have secretory granules and immunocytochemically are growth hormone or prolactin-positive, despite no associated clinical changes or abnormal serum hormone levels about 5 per cent of the time. Inactive tumors have cells with no histologic, immunocytologic, or electron microscopic markers (Null cells). They are chromophobic and electron microscopy show them to have poorly developed cytoplasm, indented nuclei, and sparse granules (100 to 250 lim) lined up along the cell membrane.

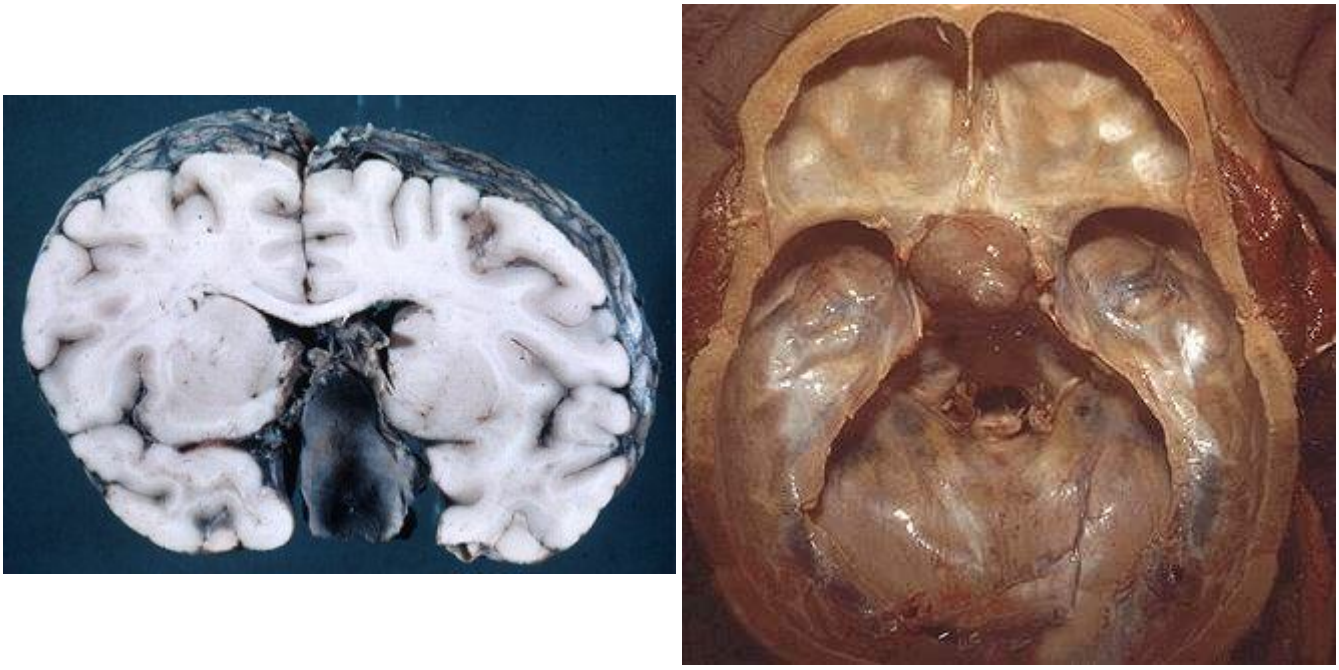

Figure 1. **Nonfunctioning pituitary adenomas with suprasellar extension**

It is the functionally active group of pituitary tumors that comprise the largest percentage of pituitary adenomas. They represent about 75 per cent of all pituitary tumors. Preoperative endocrinologic testing, as well as clinical symptomatology resulting from the adenoma's hypersecretion of hormones, helps to identify and classify these tumors. It is this functional classification confirmed with immunohistochemical and immunoelectromicroscopic techniques and not traditional light microscopic pathology that separates these tumors.

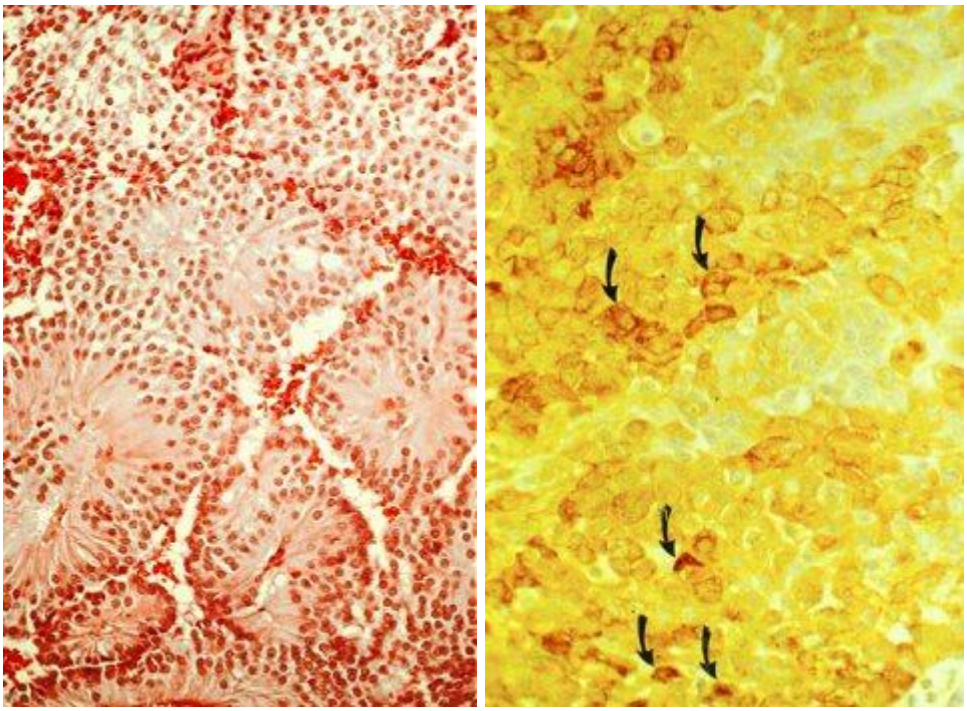

Figure 2. **A, Pituitary Adenoma, the tumor is composed of cylindrical cells with a distinct perivascular arrangement. The similarity with a perivascular pseudorosette is quite apparent. This tumor can be easily confused with an ependymoma. B, Pituitary adenoma that has been immunostained with an antibody directed against corticotrophin.**

Prolactinomas represent about 40 to 50 per cent of all patients with pituitary adenomas. Under light microscopy, prolactin cell tumors are chromophobic or acidophilic. Using immunoelectron microscopy, they may be classified as densely or sparsely granular, although the former type is quite rare. The densely granular resemble nontumor lactotrophic pituitary cells that are resting and nonsecreting. The sparsely granular type resemble the nontumor lactotrophic pituitary cells that are actively secreting. Their secretary granules are sparse, spherical, and measure 150 to 350 nm.

Somototrophic adenomas, resulting in acromegaly, account for 15 to 25 per cent of pituitary adenomas. Under light microscopy, these tumors may be termed acidophilic or chromophobic. Using immunoelectron microscopy, two distinct cell types can be identified: densely and sparsely granulated adenomas. The densely granulated cell type more closely resembles nontumor pituitary somototrophic cells and is characterized by well-developed endoplasmic reticulum, permanent Golgi complexes, and numerous spherical densely staining secretary granules. The sparsely granulated type differ from nontumorous pituitary somototrophic cells in that it has permanent Golgi complexes, irregular nuclei, few spherical secretary granules, and several centrioles.

Cushing's disease or Nelson's syndrome caused by corticotropin-secreting adenomas represent only about 5 per cent of all pituitary adenomas. Under light microscopy, corticotrophs are basophilic. Immunoelectron microscopy shows these tumor cells to be similar to corticotrophic nontumorous pituitary cell types containing numerous spherical secreting granules that vary in density, measure 250 to 700 nm, and line up along the cell membranes.

The rarest of pituitary adenomas are those that secrete solely thryotrophin or gonadotropin. Each type accounts for less than 1 per cent of pituitary adenomas. Under light microscopy, the thyrotropic adenomas are chromophobic and under electron microscopy, they have long cytoplasmic processes, sparse, spherical secreting granules (150 to 250 nm), and abundant endoplasmic reticulum.

TYPE OF ADENOMA	PERCENTAGE
NONFUNCTIONING ADENOMA	25%
PROLACTINOMAS	40%-50%
ACIDOPHILE ADENOMA [GROWTH HORMONE]	15%-25%
ACTH SECRETING ADENOMA	5%
OTHERS	< 1%

Pituitary macroadenomas are, by definition, at least 10 mm in size or more, while microadenomas are less than 10 mm in size.

Patients with functional adenomas present with endocrine symptoms and, consequently, smaller lesions (microadenomas). It is therefore more typical for macroadenomas to cause symptoms related to compression of adjacent structures. Optic nerve and tract compression causes visual symptoms, including the classic presentation of bitemporal hemianopsia. If there is compression of the ventricular system or foramen of Monro, the patient presents with signs and symptoms of hydrocephalus.

Macroadenomas almost always cause sellar enlargement, which, however, is often also seen with other sellar masses. Sellar wall erosion, with infrasellar extension into the sphenoidal sinus, is more often a feature of macroadenomas than other tumors. [14] The presence of necrosis, hemorrhage is common. Intratumoral hemorrhage occurs in 20% to 30% of patients with adenomas. Macroadenomas are more

prone to hemorrhage as are tumors in patients who have been receiving bromocriptine therapy. [17,22] **Intratumoral hemorrhage can occur without clinical evidence of pituitary apoplexy.** [17]

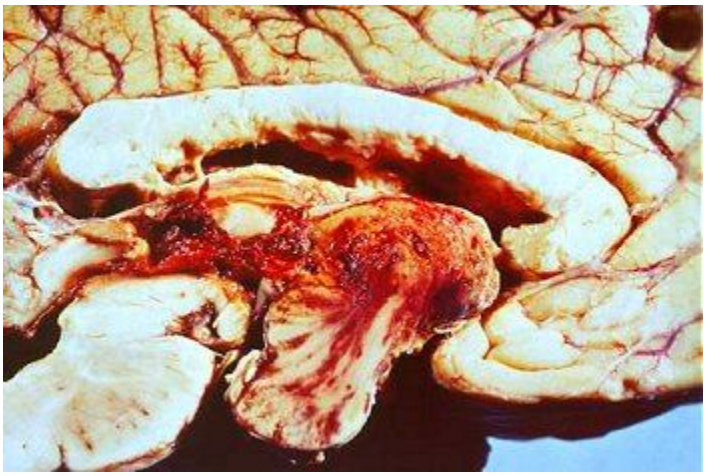

Figure 3. Sagittal view of the brain in a patient with acromegaly. Notice the very large tumor that had grown above the sella turcica and had extended into the third ventricle. Notice the presence of hemorrhage within the tumor. This is what is known as "pituitary apoplexia" a devastating neurological catastrophy with the onset of sudden blindness and frequently resulting in death

GRADING OF PITUITARY ADENOMA

GRADE	DESCRIPTION
GRADE I	Tumours have a diameter of less than 10 mm, and confined entirely within the sella. The sella might be focally expanded but remains intact [microadenoma].
GRADE II	The tumours have a diameter of 10 mm or more, the sella is enlarged, however the the sellar floor is not perforated by the tumours.
GRADE III	The tumours focally perforate the dural membrane and cortical bone of the anterior wall of the sellar floor and Extent into the sphenoid sinus.
GRADE VI	The tumours diffusely perforate the dural membrane and the cortical bone of anterior wall of the sellar floor and extent into the sphenoid sinus.

NORMAL ANATOMY OF THE PITUITARY GLAND

The pituitary gland lies within the sella turcica between the cavernous sinuses. Its density is similar to that of the sinuses and dura so that, with the possible exception of its upper surface, which is to a variable degree outlined by the chiasmatic cistern but partly covered by the pituitary diaphragm, the precise limits of the gland cannot be distinguished from the adjacent tissues on either plain or contrast-enhanced studies.

The shape and height of the pituitary gland is best assessed on the coronal views. The height should be less than 8 mm. The top of the gland should be flat or concave, and there should not be an upward convexity contour. The normal pituitary appears slightly hyperdense on the plain scan, and there is homogeneous contrast enhancement.

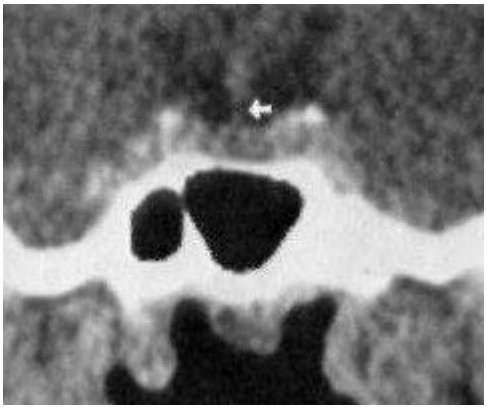

Figure 4. Normal appearance of the pituitary gland, notice the upper concave border,the diffuse enhancement of the pituitary gland and the well corticated sellar floor.

PITUITARY MICROADENOMA

These tumors may be 3 to 10 mm in size and may be located within a normal-sized sella turcica. They may cause symptoms of hormonal hypersecretion. These are most commonly caused by prolactin or growth hormone abnormalities, less commonly by adrenocorticotrophic hormone disturbances. The elevated pituitary hormone content may be caused by conditions other than pituitary neoplasms; therefore, sensitive neuroimaging studies are necessary to document the presence or absence of pituitary microadenomas.

Because of the small size of pituitary microadenomas, the measured sella volume may be within normal limits; however, even with normal size of the sella, the sellar shape and bone detail almost always show some detectable radiographic abnormalities. This may not always be detected by routine skull radiographs (or even utilizing coned-down views of the sella turcica), and these abnormalities may most sensitively be assessed by CT scan with a bone windows.

Figure 5. Intrasellar microadenoma demonstrated as a well-defined rounded mass in the lateral portion of the pituitary gland,notice the convex upper border of the gland and the erosion of the sellar floor

The most characteristic radiographic abnormal finding of pituitary microadenomas is an anterior-inferior bulge in the sella floor. This is most commonly seen in the lateral wall of the sella, correlating with the previously reported propensity of prolactin-secreting microadenomas located in the lateral portion of the pituitary gland. It has been reported that computerized tomography shows sella turcica bone abnormalities in 96 per cent of pituitary microadenomas. However, it is also important for the clinician to understand the pattern of normal variations in the development of sella turcica and the contiguous sphenoid bone. This understanding may avoid interpretative errors in assessing pituitary radiographic changes as being caused

by tumor when these changes may actually be due to normal anatomic variants.

The CT findings that are suggestive of a pituitary microadenoma include (1) height that exceeds 8 mm with an upward bulging or a convexity to the superior surface of the gland, (2) focal hypodense lesion seen within the hyperdense gland (especially after contrast enhancement due to delayed enhancement of the microadenoma), (3) upward and lateral deviation, displacement and enlargement of the pituitary stalk or infundibulum.



Figure 6. Intrasellar microadenoma demonstrated as a well-defined rounded mass in the lateral portion of the pituitary gland, notice the convex upper border of the gland and the erosion of the sellar floor

After infusion of contrast material, the microadenoma enhances more slowly than the normal pituitary gland. This results in the focal hypodense appearance of the microadenoma. If the postcontrast scan is delayed, the focal hypodensity representing the microadenoma may not be seen.

If the infundibulum (as seen on the axial section) is larger than the basilar artery (located in the interpeduncular cistern) on the enhanced scan. this is considered to be abnormal, and this finding is suggestive of a pituitary mass. The upward extension and displacement of the infundibulum due to a pituitary tumor is best seen on the coronal views. The prolactin-secreting microadenomas are equally distributed between central and lateral location within the gland; whereas growth hormone and adrenocorticotrophin-secreting microadenomas are usually more central in location. After infusion of contrast material, the microadenoma enhances more slowly than the normal pituitary gland. This results in the focal hypodense appearance of the microadenoma. If the postcontrast scan is delayed, the focal hypodensity representing the microadenoma may not be seen. Following treatment with bromocriptine, the shrinkage in the size of the pituitary mass may be well followed with serial CT.

Figure 7. Intrasellar microadenoma demonstrated as a well defined rounded hypodense mass due to delayed enhancement of the adenoma compared with the normal pituitary tissues (right postcontrast CT

scan, left postcontrast T1 MRI image)

Utilizing high-resolution computed tomography, it is possible to detect pituitary microadenomas in most cases. A complete CT scan study must include direct coronal sections that are 1.5 to 2.0 mm in thickness. However, reformatted reconstructions (which are based upon the axial views and are then generated into the coronal and sagittal planes by computer analysis) may be utilized.

MRI is more sensitive than CT scan in detecting pituitary microadenomas. It is best demonstrated on the postcontrast T1 images as a rounded hypointensity that shows significant delay in enhancement compared with the normal pituitary gland tissues.

- **Characteristic plain x ray, CT & MRI findings of pituatry microademomas**

- The most characteristic radiographic abnormal finding of pituitary microadenomas is an anterior-inferior bulge in the sella floor.
- Height that exceeds 8 mm with an upward bulging or a convexity to the superior surface of the gland.
- Focal hypodense lesion seen within the hyperdense gland especially after contrast enhancement due to delayed enhancement of the microadenoma
- Upward and lateral deviation displacement, and enlargement of the pituitary stalk or infundibulum.

PITUITARY MACROADENOMA

- **Plain x ray & CT scan imaging of pituitary macroadenoma**

The CT findings in pituitary macroadenomas are dependent upon several factors. These include size of tumor, major vector of expansion, and tumor pathologic characteristics. If the pituitary adenoma is a solid tumor, it usually appears iso- or hyperdense (noncalcified) on the noncontrast CT, and there may be dense homogeneous sharply marginated contrast enhancement. Cystic adenomas appear as round hypodense lesions on the noncontrast CT scan, and there is usually a thin peripheral rim of enhancement. In rare instances, the cystic pituitary adenoma appears as a hypodense lesion without contrast enhancement. Hemorrhagic pituitary adenomas usually appear as hyperdense noncalcified lesions on the plain scan; there is dense homogeneous or peripheral rim enhancement.

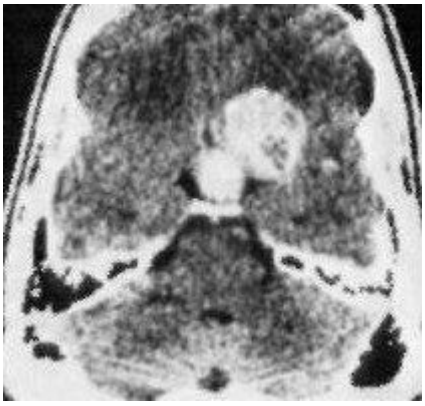

Figure 8. Suprasellar pituitary macroadenoma

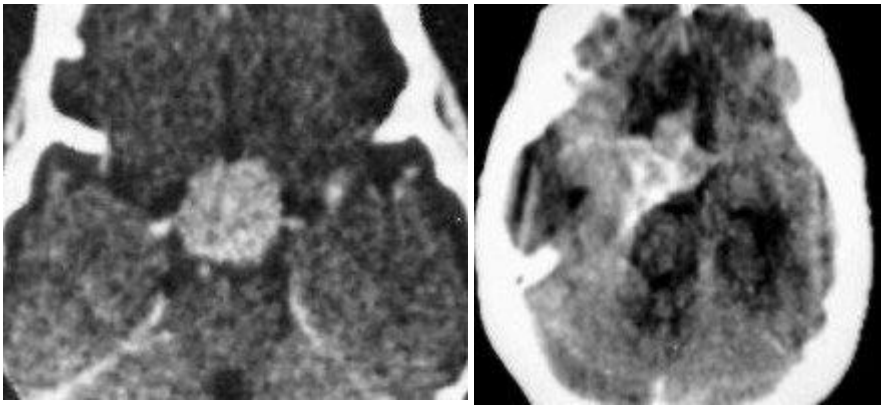

Figure 9. Suprasellar pituitary macroadenomaS

If the pituitary neoplasm, as demonstrated by CT scan contains necrotic liquefied tissue rather than solid hematoma, the plain scan may show a more mottled hypodense central region with a peripheral rim of enhancement. Invasive adenomas may appear as irregularly marginated hyperdense lesions; they may show heterogeneous enhancement. They are diffuse, widespread, and poorly marginated lesions; they also show marked bone erosion. The presence of intrasellar calcification should suggest an alternative diagnosis such as craniopharyngiomas, meningiomas, aneurysms; however, in rare instances, pituitary adenomas show evidence of calcification.

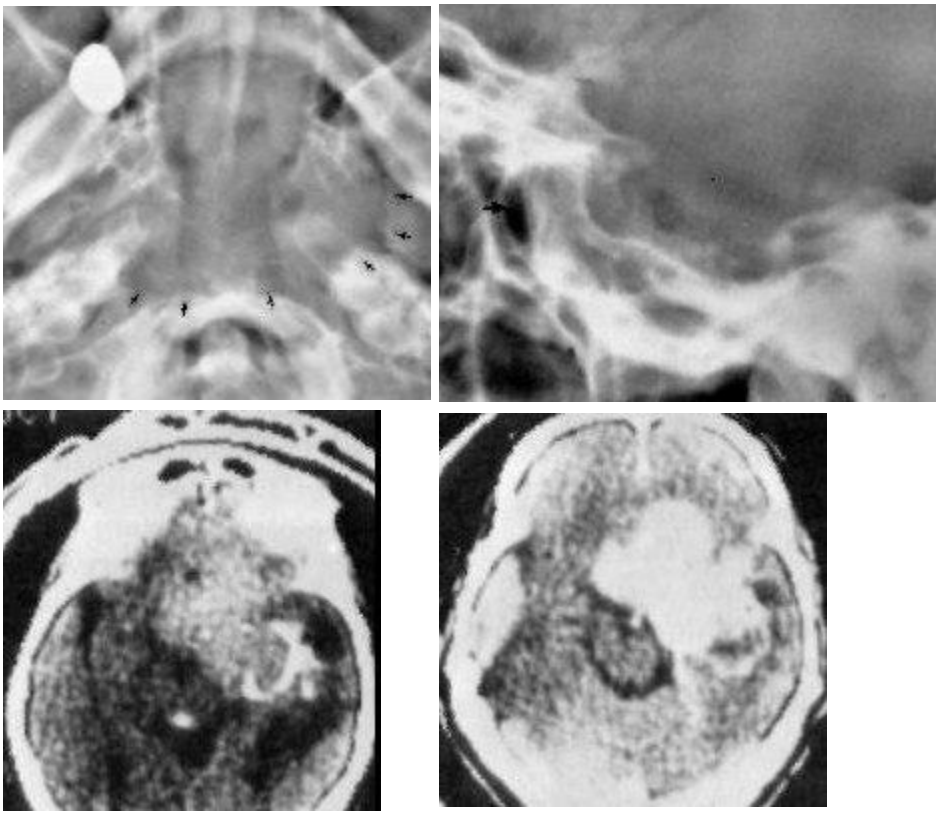

Figure 10. Invasive pituitary adenoma causing marked erosion of the sellar floor with double flooring and suprasellar extension

Because pituitary adenomas usually originate within the sella turcica, CT shows an enhancing round mass. There is usually no surrounding suprasellar cistern may be seen on axial sections.

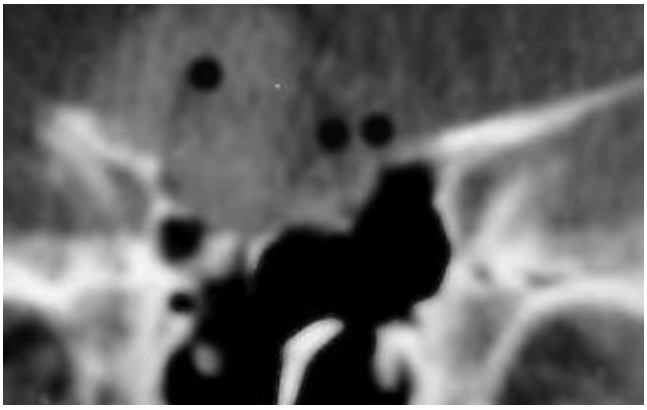

Figure 11. Pituitary macroadenoma causing unilateral depression of the sellar floor, this commonly causes double flooring when viewed by plain x ray

However, these tumors are more clearly defined on coronal and sagittal sections. The superior (extending to the intraventricular foramina and anterior third ventricle) and inferior (into the sphenoid sinus) extension of the mass is best demonstrated with coronal CT. The sphenoid sinus is located directly underneath the floor of the sella. Tumor extension into the air-filled sinus and evidence of bone erosion of the sella floor is well visualized on coronal CT. Lateral extension of the pituitary adenoma may be demonstrated by displacement of the carotid arteries, which are paired structures located in the antero-lateral portion of the suprasellar cistern.

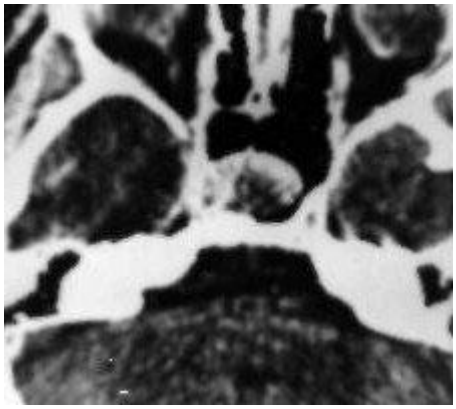

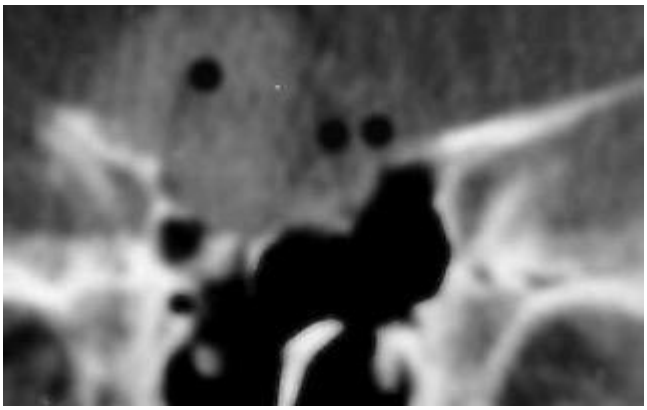

Figure 12. A,B,C Pituitary macroadenoma causing unilateral depression of the sellar floor,this commonly causes double flooring when viewed by plain x ray [A]. Erosion of the sellar floor with extension to the sphenoidal sinus is also demonstrated [B,C]

The cavernous sinuses in the parasellar region appear as paired symmetrical vertically oriented densely enhancing parasellar bands. With lateral extensions of the adenoma, the cavernous sinus appears as a broad band that is thicker ipsilateral to the tumor. The asymmetry or lateral deviation of the broad band of cavernous sinus enhancement is consistent with lateral extension of the intrasellar mass. Anterior extension of adenomas is demonstrated by the presence of an enhancing mass located within the anterior

portion of the suprasellar cistern. With more significant anterior extension, there are enhancing lesions in the frontal region seen with surrounding hypodensities. If there is posterior extension, there is distortion and posterior displacement of the interpeduncular cistern and basilar artery. Rarely, pituitary adenomas extend to the intraventricular foramina to cause obstructive hydrocephalus; however, this finding is more common with suprasellar masses such as craniopharyngiomas.

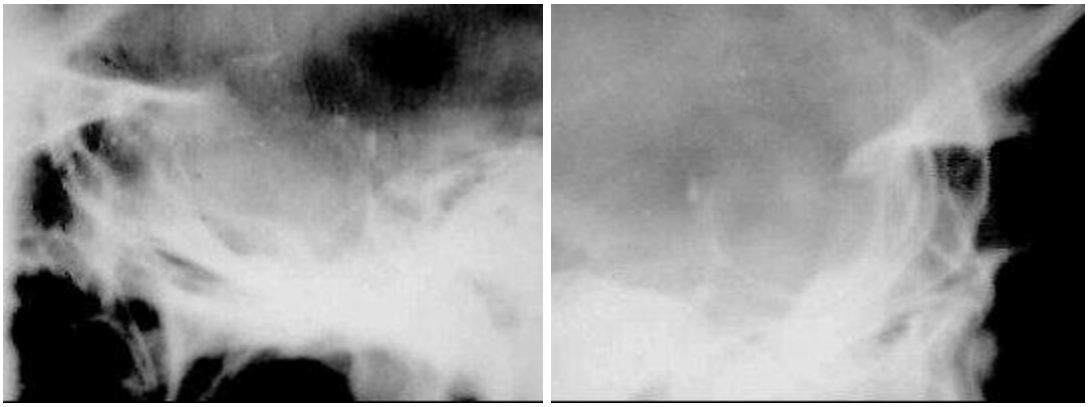

Figure 13. Enlargement of the sella turcica with double flooring and erosion of the dorsum sellae and posterior clinoids, the plain x ray characteristics of pituitary adenomas

- **MRI imaging of pituitary macroadenoma**

MR imaging of pituitary lesions is preferable to CT because one avoids beam hardening artifact and can evaluate better adjacent structures, such as the optic nerves and chiasm and cavernous sinuses. If clips are placed at surgery, significant artifact is encountered on postoperative CT examinations, whereas this presents less of a problem with MR imaging.

Pituitary macroadenomas are, by definition, at least 10 mm in size. They are well visualized on Tl-weighted coronal images. In this plane, they can usually be differentiated from optic chiasm pathology. Coronal imaging also avoids partial volume artifact from the sphenoid sinus and carotid arteries. The relationship of the pituitary to the cavernous sinuses can also be assessed. CT can detect destruction of the floor of the sella, whereas MR imaging cannot. MR imaging clearly demonstrates tumor invasion of the sphenoid sinus and clivus, which may be more relevant clinically

Macroadenomas almost always cause sellar enlargement, which, however, is often also seen with other sellar masses. Sellar wall erosion is more often a feature of macroadenomas than other tumors. [14] The presence of necrosis, hemorrhage, or both in these lesions causes the variable appearance of macroadenomas on MR imaging. Generally, macroadenomas have signal intensity similar to gray matter on Tl- weighted images and increased signal intensity on T2-weighted images. Cystic changes or necrosis is seen in 5% to 18% of macroadenomas. [14] In the presence of necrosis, there is a relative decrease in signal on Tl -weighted images and increase in signal on T2-weighted images. Enhancement of adenomas generally is mild and inhomogeneous, particularly when necrosis is present. A lesion with central necrosis can be difficult to distinguish from a pituitary abscess.

Pituitary abscesses can occur in patients with a sellar mass, such as an adenoma, Rathke's cleft cyst, or craniopharyngioma. [23] Presenting symptoms vary and may be similar to those of a macroadenoma rather than of an infectious process. [15] In the absence of hemorrhage, signal characteristics generally are those of

a cystic lesion. In typical cases, MR imaging with intravenous contrast administration demonstrates a lesion with peripheral rim enhancement and central low intensity. [15,21] This may appear similar to an adenoma with necrosis, as described earlier. If present, meningeal enhancement can assist in making the diagnosis of pituitary abscess. [21]

Intratumoral hemorrhage occurs in 20% to 30% of patients with adenomas. Macroadenomas are more prone to hemorrhage as are tumors in patients who have been receiving bromocriptine therapy. [17,22] Intratumoral hemorrhage can occur without clinical evidence of pituitary apoplexy. [17] Blood products may shorten Tl relaxation times leading to high signal foci within the adenoma as well as causing variable changes to T2 images. Because of the increased T1 signal, an adenoma with hemorrhage may be mistaken for a craniopharyngioma. The presence of a fluid level in the lesion is more suggestive of hemorrhage. The use of NMR spectroscopy to differentiate between adenomas and other parasellar masses, such as meningiomas, is experimental. [12,13] The distinction between meningioma and pituitary adenoma is important because of the different surgical approach (craniotomy) used in the treatment of the former. [21]

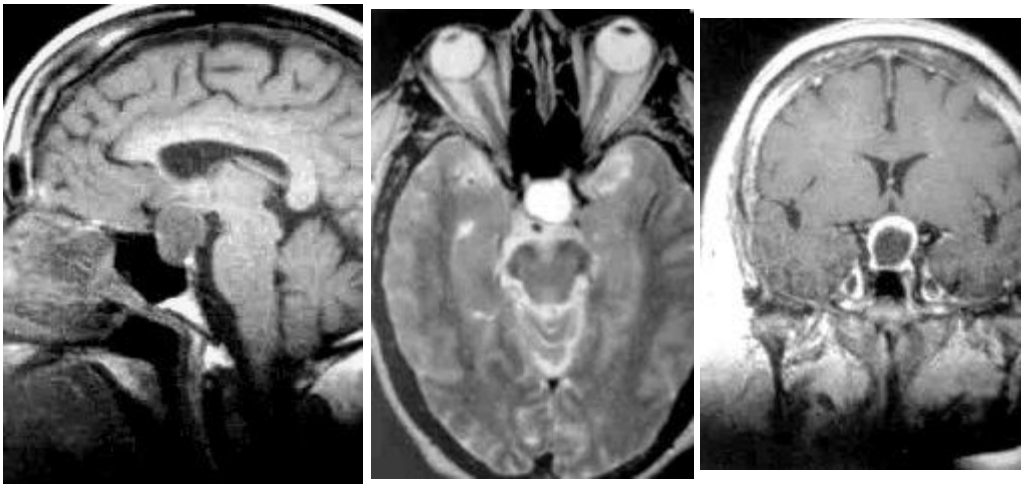

Figure 14. Pituitary macroadenoma. A 63-year-old woman imaged because of chronicheadaches.The patient had no visual symptoms or endocrinea bnormalities. A, Sagiftal Tl -weighted image demonstrates an intrasellar and suprasellar mass. There is expansion of the bony margins of the sella. The signal within the lesion is less than that of the adjacent brain but more than that of CSF. Findings are consistent with central necrosis. B, T2-weighted axial image demonstrating fluid intensity signal within the mass. Again, the signal intensity is different from that of CSF. C, There is enhancement of the periphery of the lesion after administration of gadolinium.

The extent of tumor is generally well evaluated by MR imaging. Because the medial dural reflection is not seen on MR images, however, evaluation of cavernous sinus invasion by pituitary adenomas is difficult. Invasion of the cavernous sinus occurs in 6% to 10% of pituitary adenomas. [16] The presence of abnormal tissue between the lateral wall of the cavernous sinus and the carotid artery is the most reliable imaging manifestation of invasion. [16,18] A high serum prolactin level (1000 ng/mL) also correlates with cavernous sinus involvement. [19]

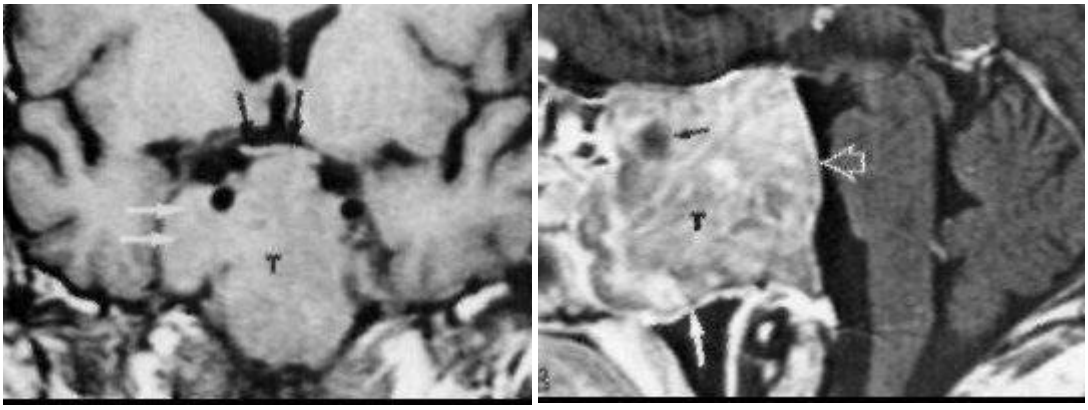

Figure 15. Huge pituitary adenoma demonstrated by MRI ,T1 image (A), the tumour show intense, but inhomogeneous postcontrast enhancement, with cystic changes (B)

Enlargement of pituitary adenomas during pregnancy is well documented and may be demonstrated by CT and MRI. Rarely hypopituitarism can develop in previously normal women during pregnancy or the postpartum period associated with extensive infiltration of the gland by lymphocytes and plasma cells, referred to as lymphocytic hypophysitis. CT reveals sellar enlargement by a homogeneously enhancing mass bulging into the suprasellar region.

CONTRAST ISSUES IN PITUITARY ADENOMAS

The general principles of MR imaging contrast dosage and image timing are not necessarily applicable to the imaging of pituitary adenomas. The normal pituitary gland enhances after contrast administration because it lacks a blood-brain barrier. Therefore, enhancing tissue may partially or totally surround lesions arising from the gland. In the case of macroadenomas, this situation does not present a significant problem because these tumors are not symptomatic until they have reached a relatively large size and impinge on structures external to the sella turcica, such as the optic chiasm. At this point, macroadenomas can be seen as a mass expanding or extending out of the sella turcica, and contrast material is not necessary for detection of the tumor. Pituitary microadenomas have different imaging considerations. Although often hormonally active, they are by definition small (<l cm) and may not be detectable by mass effect alone. Microadenomas generally enhance to a lesser degree than normal pituitary tissue. Therefore, they must be perceptible as a low-intensity focus compared with the rest of the gland after Gd contrast administration. Davis et al, [24] found that use of half-dose contrast material may be equal to or superior to full dose for imaging microadenomas. The decreased dose may prevent obscuration of the adenoma by intense enhancement in the rest of the gland. Half-dose imaging may also help delineate the cavernous sinus better than full dose.

Image timing may also be an important factor for improved adenoma detection. Hayashi et al, [25] performed dynamic imaging of the pituitary during and just after slow hand injection (approximately 90-second injection time) over a total period of 350 seconds. They found that the maximal contrast of adenoma to the normal pituitary occurred between 145 and 300 seconds. Miki et al, [26] used dynamic imaging at 1-minute intervals after intravenous bolus injection of a standard dose (0.1 mmol/kg) of gadopentetate, with heavily Tl-weighted images (TR = 100, TE = 15), in patients with pituitary adenomas (microadenomas and macroadenomas). They reported maximal visual contrast between tumor and normal gland at either 1 or 2 minutes after injection in all cases, and there was improvement in contrast over a usual (nondynamic) imaging protocol in all cases. The preponderance of data on imaging pituitary adenomas suggests that half-dose contrast material may be used with equal or improved results to standard dose and that sensitivity

may be increased with dynamic imaging.

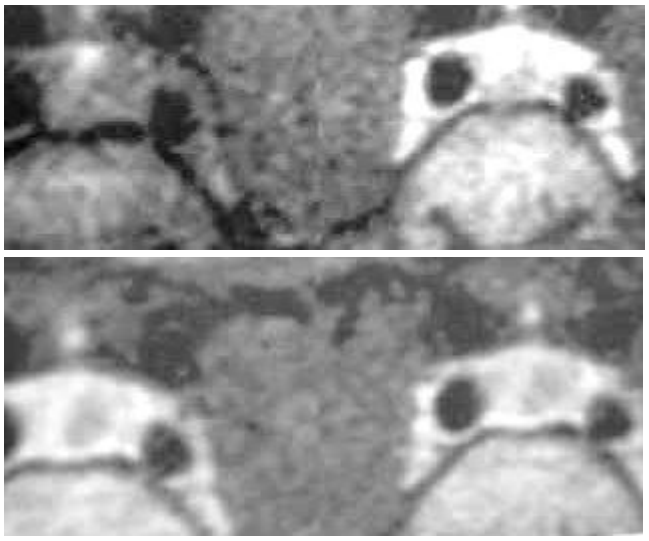

Figure 16. Dynamic MR images of the pituitary in a 32-year-old woman with hyperprolactinemia. Four images from a dynamic pituitary study just before (upper left) and 60 seconds (upper right), 90 seconds (lower left), and 120 seconds (lower right) after injection of gadopentetate dimeglumine show a hypointense lesion in the left sella compatible with a microadenoma.

PITUITARY APOPLEXY

Pituitary apoplexy is due to infarction of or haemorrhage into a pituitary adenoma. Infarction may be indistinguishable from a low density pituitary swelling and may or may not show enhancement. Haemorrhagic pituitary apoplexy may reveal high density within the adenoma or brain substance or subarachnoid space in the acute phase and low density with or without marginal enhancement as the haematoma is absorbed. This condition will probably be considered by the clinician when an appropriate syndrome occurs in a patient known to have a pituitary adenoma, but pituitary tumours may first present as subarachnoid haemorrhage.

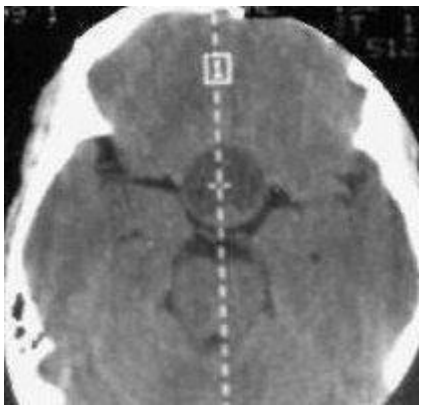

Figure 17. CT scan picture of pituitary apoplexy showing a hypodense rounded cystic suprasellar mass with enhancing walls

The correct diagnosis should be recognized from CT or suspected from sellar erosion on plain films prior to neuroimaging studies. Pituitary apoplexy commonly results in spontaneous involution of the pituitary adenoma and if the patient survives, this might result in empty sella.

EMPTY SELLA SYNDROME

In patients with radiographic and polytomographic evidence of an abnormal sella turcica, it is important to differentiate a pituitary mass lesion, such as pituitary macroadenomas, intrasellar cysts, intrasellar aneurysms, from intrasellar cisternal herniation (an empty sella). In the empty sella syndrome, the sella

turcica is enlarged, usually with none or only minimal bone erosion; however, bone erosion-identical to that seen in pituitary neoplasms may be seen in some cases. In the empty sella, the pituitary gland is flattened and atrophic; it is located in the posterior-inferior portion of the sella turcica. CT shows evidence of CSF-density extending into the sella turcica on both the coronal and sagittal views.

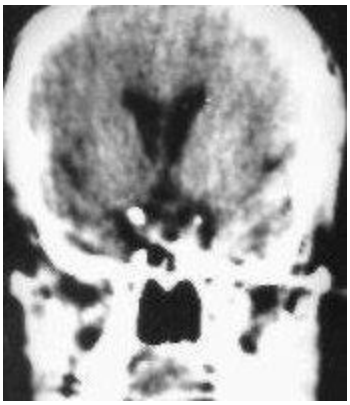

Figure 18. Empty sella, notice the intrasellar extension of the suprasellar cistern with intrasellar CSF attenuation values

There is no evidence of abnormal intrasellar enhancement. With thin section CT, the pituitary infundibulum may be seen extending downward into the sella. This is the most important point in differentiating an empty sella from a pituitary adenoma. In some cases, the diagnosis of an empty sella may only be established with metrizamide CT cisternography. The diagnosis is established by the finding of opacification of the intrasellar cistern. Metrizamide CT cisternogram is frequently necessary to differentiate an intrasellar subarachnoid cyst or a pituitary micro- or macroadenoma from an empty sella. It is important to be aware that surgically proved hormonally secreting pituitary microadenomas have occurred in patients with CT evidence of an empty sella.

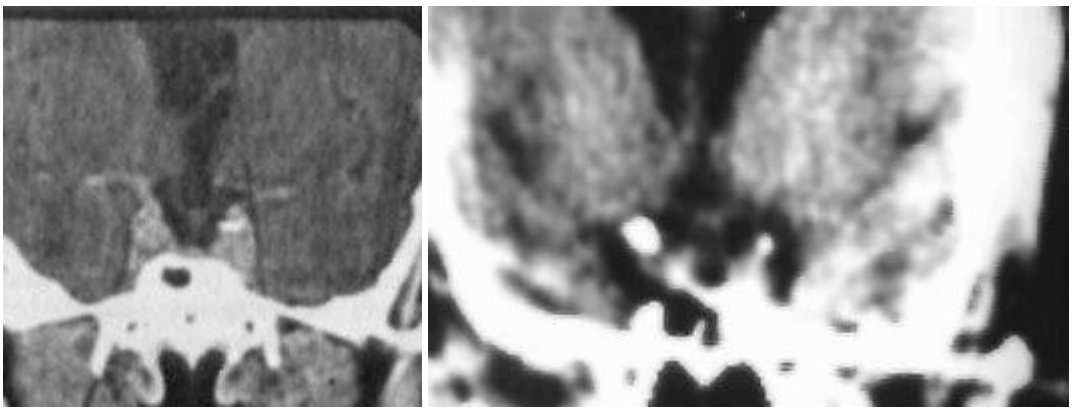

Figure 19. Empty sella, notice the intrasellar extension of the suprasellar cistern, with intrasellar CSF attenuation values

Empty sella may complicate a pituitary tumour or occur in the presence of a microscopically normal pituitary gland. The first type may follow surgery or therapy for pituitary neoplasm.

In patients with a deficient pituitary diaphragm, intrasellar extension of the chiasmatic cistern may cause enlargement of the sella turcica and compress the normal pituitary gland to the periphery of the enlarged sella. Such patients are usually discovered when a skull radiograph is taken for investigation of an unrelated condition such as non-specific headache or trauma. The sella is usually symmetrically enlarged and commonly disproportionately deep or quadrangular in shape, although it may be asymmetrical or

ballooned and thus simulate a pituitary tumour. High resolution thin CT sections of the pituitary fossa will show that the sellar contents are of CSF attenuation; the infundibulum can usually be traced lying closer to the dorsum than the anterior wall of the sella and extending down to the thinned pituitary gland, sometimes as little as I mm in depth, lying adjacent to the floor. The appearances are confirmed by coronal and sagittal reformatting. If head scanning shows no additional abnormality further investigation is contraindicated.

Figure 20. A case of an empty sella syndrome, notice ballooning of the sella turcica with intrasellar CSF attenuation values

However, in a patient with deficiency of the Pituitary diaphragm empty sella may be a complication of raised intracranial pressure It is most commonly associated with pseudotumour cerebri and therefore in obese or hypertensive women, but sometimes with convexity block to CSF flow and with intracranial tumours. In such conditions visual field defects and visual loss may be caused by intrasellar herniation of the optic chiasm or nerves, and erosion of the walls of the sella may result in a fistula into the sphenoid air sinus, causing CSF rhinorrhoea and/or fluid in the sinus.

Pituitary apoplexy is due to infarction of or haemorrhage into a pituitary adenoma. Infarction may be indistinguishable from a low density pituitary swelling and may or may not show enhancement. Haemorrhagic pituitary apoplexy may reveal high density within the adenoma or brain substance or subarachnoid space in the acute phase and low density with or without marginal enhancement as the haematoma is absorbed.

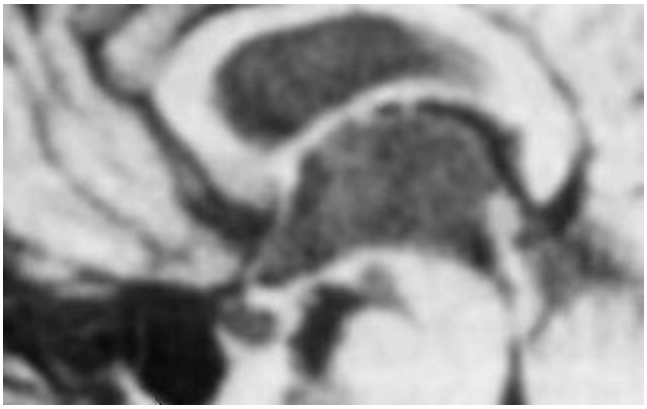

Figure 21. A case of obstructive hydrocephalus showing enlargement of the third ventricle with intrasellar herniation causing an empty sella

This condition will probably be considered by the clinician when an appropriate syndrome occurs in a patient known to have a pituitary adenoma, but pituitary tumours may first present as subarachnoid

haemorrhage. The correct diagnosis should be recognized from CT or suspected from sellar erosion on plain films prior to angiography. Pituitary apoplexy is one cause of spontaneous regression of pituitary adenoma and of empty sella.

References

1. Conomy JP, Ferguson JH, Brodkey JS: Spontaneous infarction in pituitary tumors: Neurologic and therapeutic aspects. Neurology 1975; 25: 580-587.

2. David, NJ, Gargano FP, Glaser JS: Pituitary apoplexy in clinical perspective. Neurophthalmology Symposium. St Louis, CV Mosby 1975; 8: 140-165.

3. Dawson BH, Kothandaram P: Acute massive infarction of pituitary adenomas. J Neurosurg 1972; 37: 275-279.

4. Gharib H, Frey HM, Laws ER: Coexistent primary empty sella syndrome and hyperprolactinemia. Arch Intern Med 1983; 143: 1383-1386.

5. Greenberg H S, Chandler W F, Sandler H M: Pituitary Tumors. Brain Tumors 1999; pp 257-268.

6. Levy A, Lightman SL: Diagnosis and management of pituitary tumors. B M J 1994; 308: 1087-1091.

7. Melmed S: Acromegaly. New Eng J of Med 1990; 322: 966-977.

8. Molithch ME: Pregnancy and the hyperprolactinemic woman. New Eng J of Med 1985; 312: 1364-1370.

9. Oldfield EH, Doppman JL, Nieman LK: Petrosal sinus sampling with and without corticotrophin-releasing hormone for the differential diagnosis of Cushing's syndrome. New Eng J of Med 1991; 325: 897-905.

10. Orth DN: Cushing's syndrome. New Eng J of Med 1995; 332: 791-803.

11. Thorner MO, Vance ML, Laws ER: The Anterior Pituitary. In Williams (ed), Textbook of Endocrinology. Philadelphia: W. B. Saunders, 1998; 249-340.

12. Arnold DL, Emrich JF, Shoubridge EA, et al: Characterization of astrocytomas, meningiomas, and pituitary adenomas by phosphorous magnetic resonance spectroscopy. J Neurosurg 74:447-453, 1991

13. Castillo M, Kwock L: Proton magnetic resonance spectroscopy of brain tumors. In Mukhei SK (ed): Clinical Applications of MR Spectroscopy. New York, Wiley- Liss, 1998, p 69

14. Donovan JL, Nesbit GM: Distinction of masses involving the sella and suprasellar space: Specificity of imaging features. AJR Am J Roentgenol 167:597-603, 1996

15. Guigui J, Boukobza M, Tamer 1, et al: Case report: MRI and CT in a case of pituitary abscess. Clin Radiol 53:777-779,1998

16. Knosp E, Steiner E, Mtz K, et al: Pituitary adenomas with invasion of the cavernous sinus space: A magnetic resonance imaging classification compared with surgical findings. Neurosurgery 33:610-618, 1993

17. Ostrov SG, Quencer RM, Hoffman JC, et al: Hemorrhage within pituitary adenomas: How often associated with pituitary apoplexy syndrome? AJNR Am j Neuroradiol 10:503-510,1989

18. Scotti G, Yu CY, Dillon WP, et al: MRI of cavernous sinus involvement by pituitary adenomas. AJR Am J Roentgenol 151:799-806, 1988

19. Shucart WA: Implications of very high serum prolactin levels associated with pituitary tumors. j Neurosurg 52:226-228, 1980

20. Taylor SL, Barakos JA, Harsh GR 4th, Wilson CB: Magnetic resonance imaging of tuberculum sellae meningiomas: Preventing preoperative misdiagnosis as pituitary macroadenoma. Neurosurgery 31:621-627, 1992

21. Wolansky Lj, Gallagher JD, Heary RF: MRI of pituitary abscesses: Two cases and a review of the literature. Neuroradiology 39:499-503,1997

22. Yousem DM, Arrington JA, Zinreich Sj, et al: Pituitary adenomas: Possible role of bromocriptine in intratumoral hemorrhage. Radiology 170:239-243, 1989

23. Domingue JN, Wilson CB: Pituitary abscesses: Report of 7 cases and review of the literature. J Neurosurg 46:601-608, 1977

24. 7. Davis PCGokhale KA, Joseph Gj, et al: Pituitary adenoma: Correlation of half-dose gadolinium-enhanced MR imaging with surgical findings in 26 patients. Radiology 180:779-784, 1991

25. 16. Hayashi S, Ito K, Shimada M, et al: Dynamic MRI with slow hand injection of contrast material for the diagnosis of pituitary adenoma. Radiat Med 13:167-170, 1995

26. 31. Miki Y, Matsuo M, Nishizawa S, et al: Pituitary adenomas and normal pituitary tissue: Enhancement pattern on gadopentetate-enhanced MR imaging. Radiology 177:35-38,1990

- **Addendum**

  - A new version of this software is uploaded in my web site every month (it remains available for one month and is changed with the monthly update of the neurology bulletin.)

  - To download the current version follow the link "http://neurology.yassermetwally.com/topic.zip".
  - You can also download the current version from within the publication or go to my web site at "http://yassermetwally.com" to download it.
  - At the end of each year, all the publications are compiled on a single CD-ROM, please contact the author to know more details.
  - Screen resolution is better set at 1024*768 pixel screen area for optimum display